

عمليات الدكتور احمد الزغول

واقع وحقائق

عام 2000 – 2010
عام 2000 – 2010

إعداد : الدكتور أحمد الزغول

بِسْمِ اللَّهِ الرَّحْمَنِ الرَّحِيمِ

قال سبحانه وتعالى ﴿وقل اعملوا فسيرى الله عملكم

ومرسله والمؤمنون وستردون إلى عالم الغيب والشهادة

فينبئكم بما كنتم تعملون﴾

صدق الله العظيم

المحتويات

رقم الصفحة	الموضوع	رقم الصفحة	الموضوع
24	الحالة (3) (cholecystectomy colonic tumor)	10	السيره الذاتيه
26	الحالة (4) Quarrel chest stab wound , neck& abdomen stab wounds	12	الفصل الأول (أعداد العمليات الجراحيه)
29	الحالة (5) hug sliding hernia adhere to appendix)	16	الفصل الثاني العمليات الجراحيه المرجه (Critical cases)
31	الحالة (6) (laparatomy intestinal obstruction)	19	الحاله (1) (RTA) major blood vessel's injury
33	الحالة (7) (laparatomy ilio cycle stoked mass)	21	الحالة (2) Gun shot in the abdomen
35	الحالة (8) (neck stab wounds)		

54	الحالة (17) Laparotomy perforated D.U	37	الحالة (9) Irreducible huge umbilical hernia
56	الحالة (18) Quarrel abdominal stab wound	40	الحالة (10) (RTA splenic injury spleenectomy)
58	الحالة (19) Shot gun	42	الحالة (11) (huge epigastric hernia , mish repair)
61	الحالة (20) Total LF thyroid lobectomy		الحالة (12) Mild F.D late splenic rupture hematoma
63	الحالة (21) Intestinal obstruction	46	الحالة (13) (right gluteal mass)
65	الحالة (22) Perforated D.U	48	الحالة (14) (laparotomy sigmoid tumor)
67	الحالة (23) Penetrating abdominal stabe wound	50	الحالة (15) Epigastric stab wound
69	الحاله (24) Gangrenous mickels diverticulum	52	الحالة (16) Quarrel abdominal stab wound

85	الحالة (32) Cesarean section & appendectomy	71	الحالة (25) Pancreatitis ,intestinal obstruction& appendectomy
87	الحالة (33) Hydrops of the G.B Cholecystectomy	73	الحالة (26) Direct + sliding hernia
89	الحالة (34) Near total thyroidectomy	75	الحالة (27) Perforated appendix + mickels diverticulum
91	الحالة (35) Perforated duodenal ulcer	77	الحالة (28) Irreducible Lf inguinal hernia
		79	الحالة (29) Ovariactomy , cystectomy & appendectomy
		81	الحالة (30) Breast mass quadrectomy & lumpectomy
		83	الحالة (31) Cholecystectomy ,

بسم الله الرحمن الرحيم

المقدمة :

إننا نشعر جميعاً بالمسئولية الملقاة على عاتقنا أفراداً
ومؤسسات تجاه صحة الأبناء الذين هم أمانة نتحمل شرف
مسئوليتها .

لقد أدت التغيرات التكنولوجية الحديثة إلى انتشار واسع
للمركبات وحافلات النقل المختلفة وحسب إحصاءات دائرة
السير أن أعداد الحوادث في تزايد كبير . وجراء هذه
الحوادث المتكررة باستمرار سواء كانت حوادث السير ,
حوادث الطعن والقتل , أو حوادث إطلاق العيارات النارية
المختلفة بقصد أو بغير قصد . فقد كان عدد كبير من
المصابين جراء هذه الحوادث المختلفة التي تحدث في
محافظة عجلون ينقل إلى مستشفى الأيمان الحكومي |
عجلون لإجراء اللازم في سبيل إنقاذ حياتهم .

وفي هذا الكتاب سوف نسلط الضوء على الكثير من
الحالات التي وصلت إلى قسم الإسعاف والطوارئ في
مستشفى الأيمان الحكومي | عجلون بحاله سيئة جداً (بين
الحياة والموت) ومنهم من يكون في الأنفاس الأخيرة من
هذه الحياة ولكن بفضل من الله تعالى تم الأجراء اللازم

والمداخلة الجراحية الآنية في الوقت اللازم والسرعة المطلوبة وتمكنا من إنقاذ حياة تلك الفئات , بالإضافة الى كثير من الحالات الجراحية النادرة او الحالات التي كانت تتطلب عناية خاصة والتي أجريت بنجاح تام دون أي مضاعفات .

لقد احتوت طيات هذا الكتاب جزء من تلك الإنجازات وجزء من هذا التميز الذي بفضل من الله تعالى بذلنا قصارى جهدنا وأعدنا رسم البسمة ونظرة الأمل والتفاؤل على وجوه الكثير من الأسر والأفراد . أعاننا الله على فعل الخير وخدمة هذا الوطن والمواطن .

وما توفيقى إلا بالله رب العالمين . والصلاة والسلام على سيدنا محمد واله وأصحابه أجمعين .

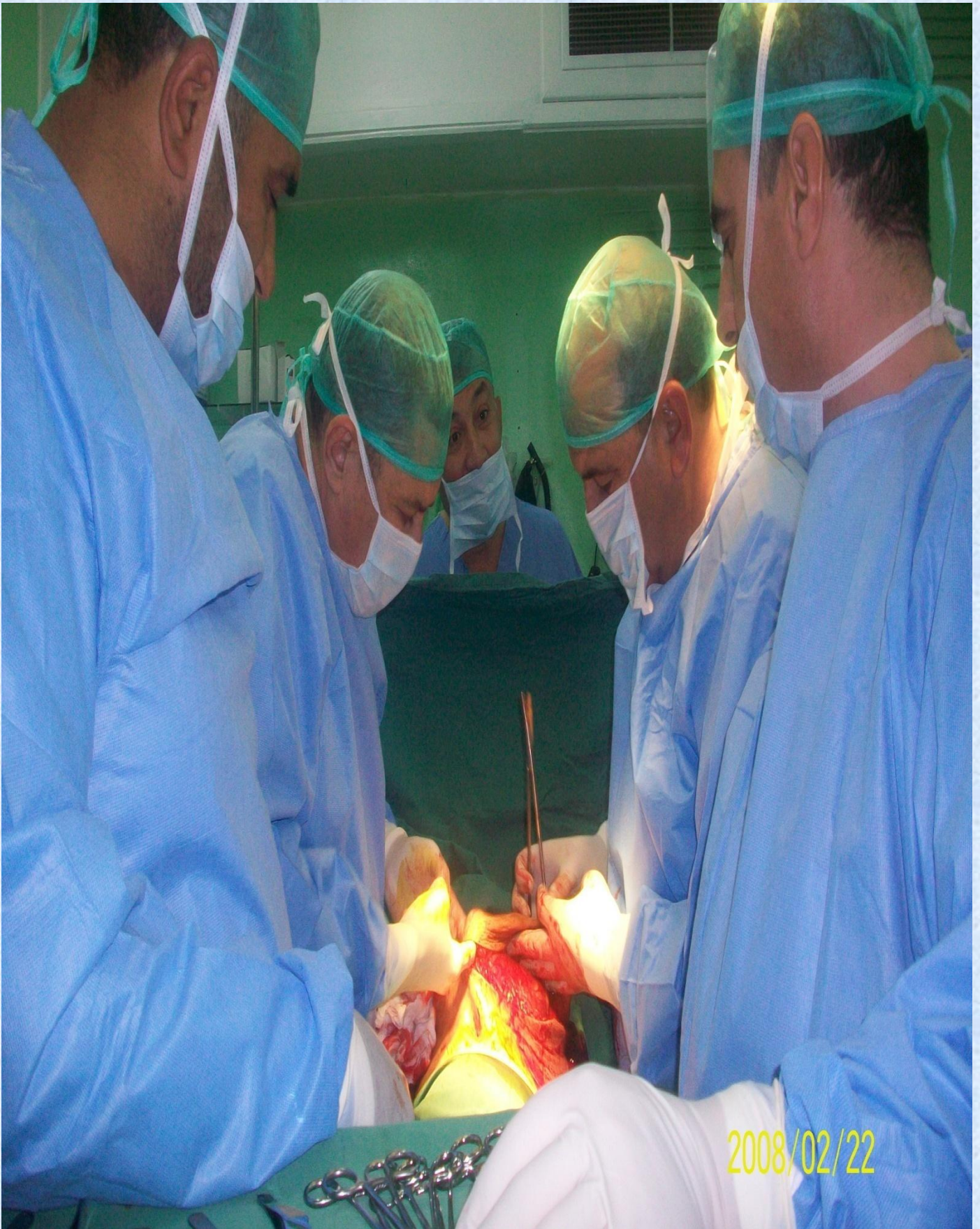الدكتور : أحمد الزغول

مدير مستشفى الأيمان الحكومي عجلون

آذار 2011

الإهداء

إلى كل من يحمل شهادة الطب الذي
احلم بأن يكون طبيباً
بارعاً ومتميزاً في أدائه وخلقه
ومدركاً لواجبه الإنساني
وخصوصاً في هذه المهنة النبيلة
ليقوم بخدمة الإنسانية على أتم وجه
والى أصحاب الضمائر الحية
والى الوطن والمواطن الذي يستحق
منا الكثير والتضحية .





السيرة الذاتية

الاسم : الدكتور احمد محمد محمود الزغول

الجنس : ذكر

الجنسية: أردني

الديانة : الإسلام

الحالة الاجتماعية : متزوج

تاريخ التعيين في ملاك وزارة الصحة : 28 /10/ 1991

المؤهل العلمي :

- البورد الأردني في الجراحة العامة اعتبارا من 1999/3/8
- بكالوريوس طب عام وجراحة 1985 سوريا – حلب

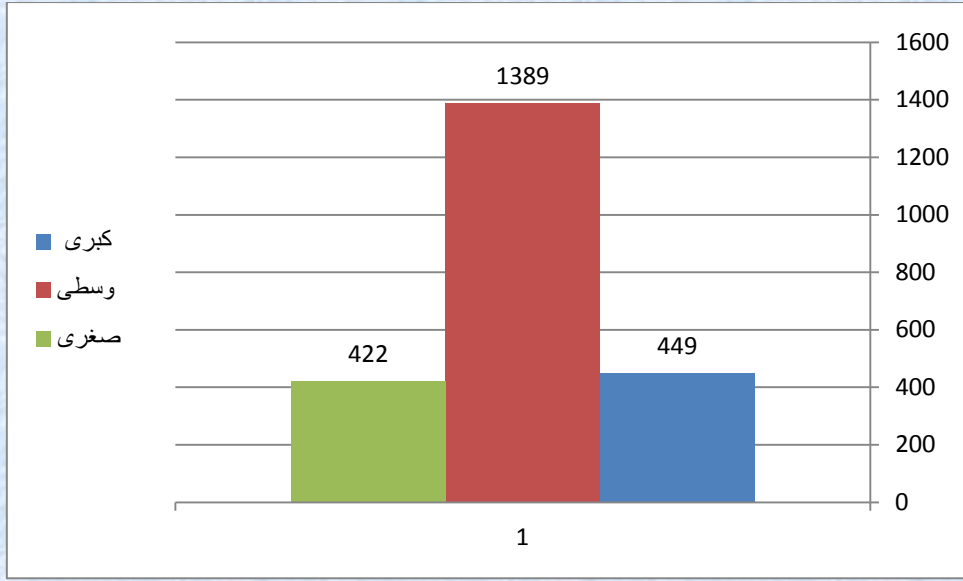
الخبرات العملية :

- مدير مستشفى الإيمان عجلون اعتباراً من 2003 /6/26
بالإضافة الى عمله رئيس قسم الجراحة العامة
- مساعداً فنياً بالإضافة الى عمله اعتباراً من 2002/6/16
- اخصائي جراحة عامة 2002/6/16-1999/3/8
- مقيم مؤهل جراحة عامة في مستشفى ابي عبيدة من
1999/4/5-1996/1/6
- مقيم جراحة عامة في مستشفى الاميرة بسمه من
1996/1/6-1991/10/28
- مقيم جراحة عامة في مستشفى الجامعة الاردنية من
1991/10/28-1989/10/6
- طبيب عام من 1989/3/25-1987/3/20 في مستشفى الامير
راشد العسكري
- طبيب امتياز في شهر 2 /1986-1987/2 في مستشفى
الاميره بسمه
الدورات التدريبية
شارك في حضور الكثير من المؤتمرات الطبية والعلمية
وشارك في العديد من الدورات التدريبية

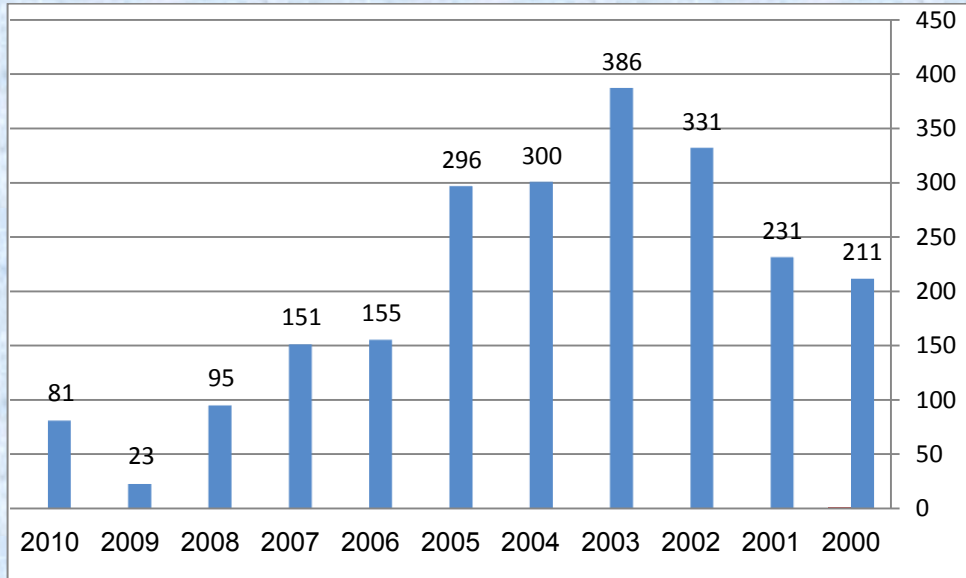
الفصل الأول
أعداد العمليات الجراحية
(2000 – 2010)

حجم العمل خلال عام 2004 – 2010 للدكتور احمد الزغول

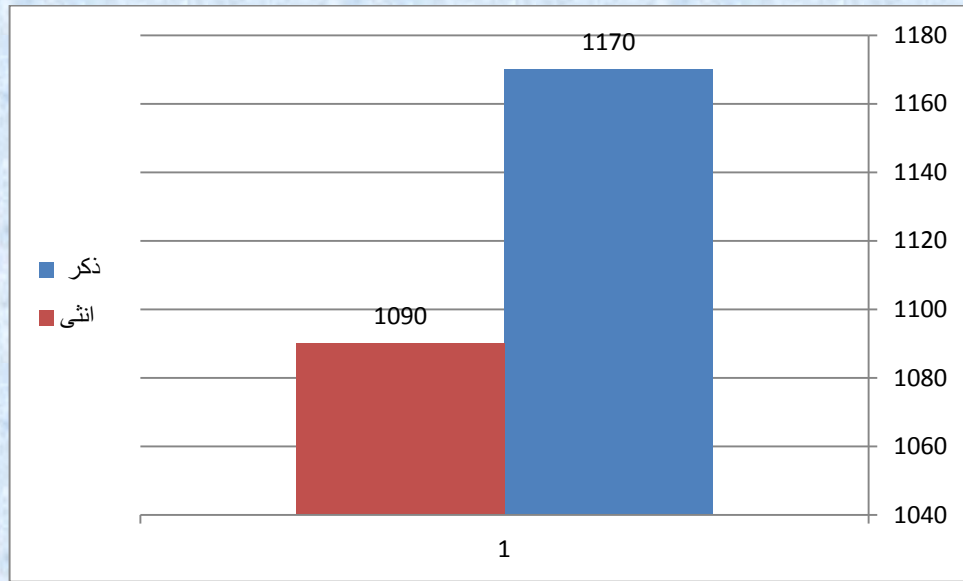
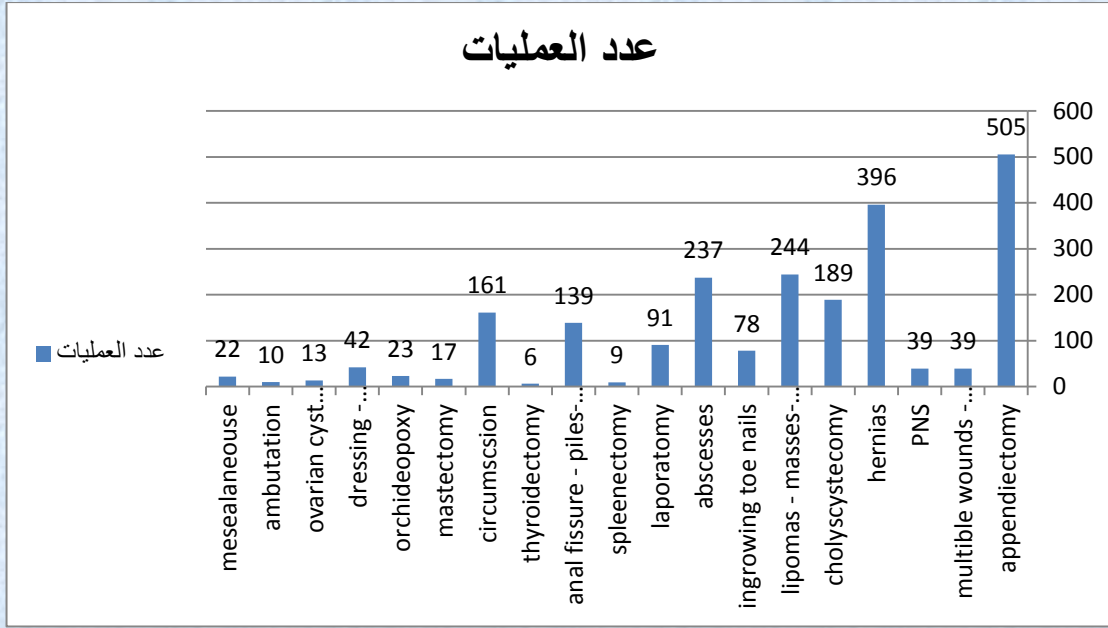
السنة	عدد المراجعين	ادخالات	التحاويل	العمليات
2004	2441	426	17	300
2005	2403	548	40	296
2006	1213	340	26	155
2007	1262	337	23	151
2008	714	153	14	95
2009	47	23	10	23
2010	496	102	15	81



أعداد عمليات الدكتور احمد الزغول موزعه
حسب نوع العملية كبرى ووسطى صغيرة



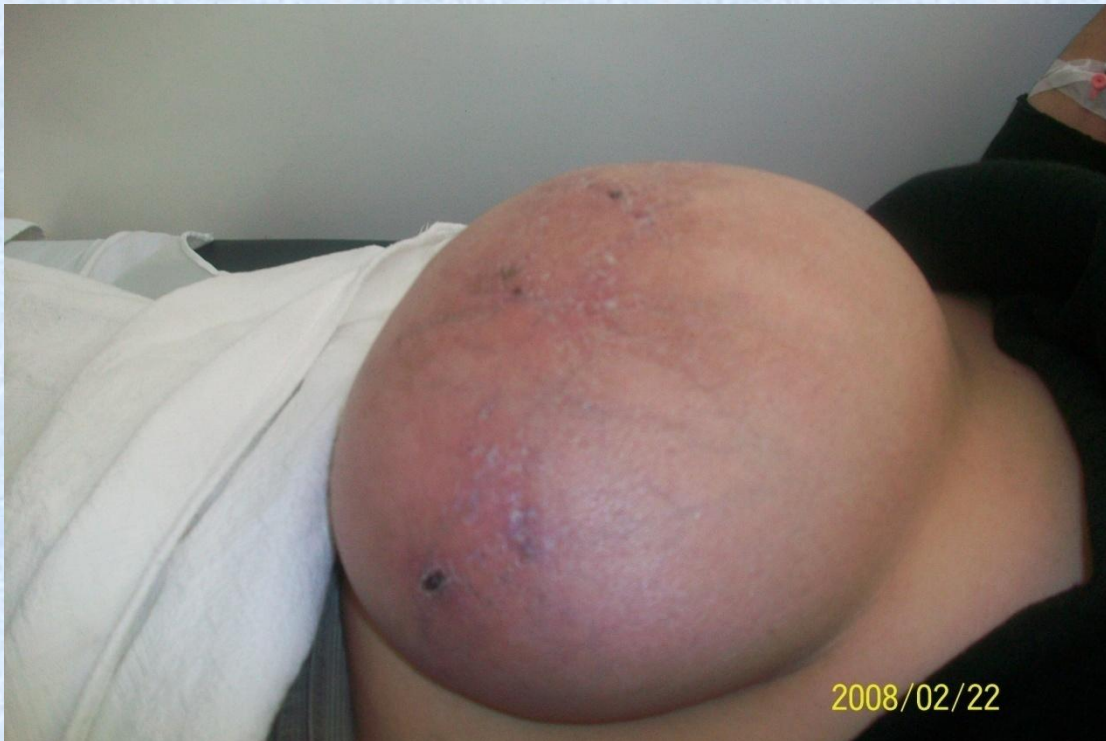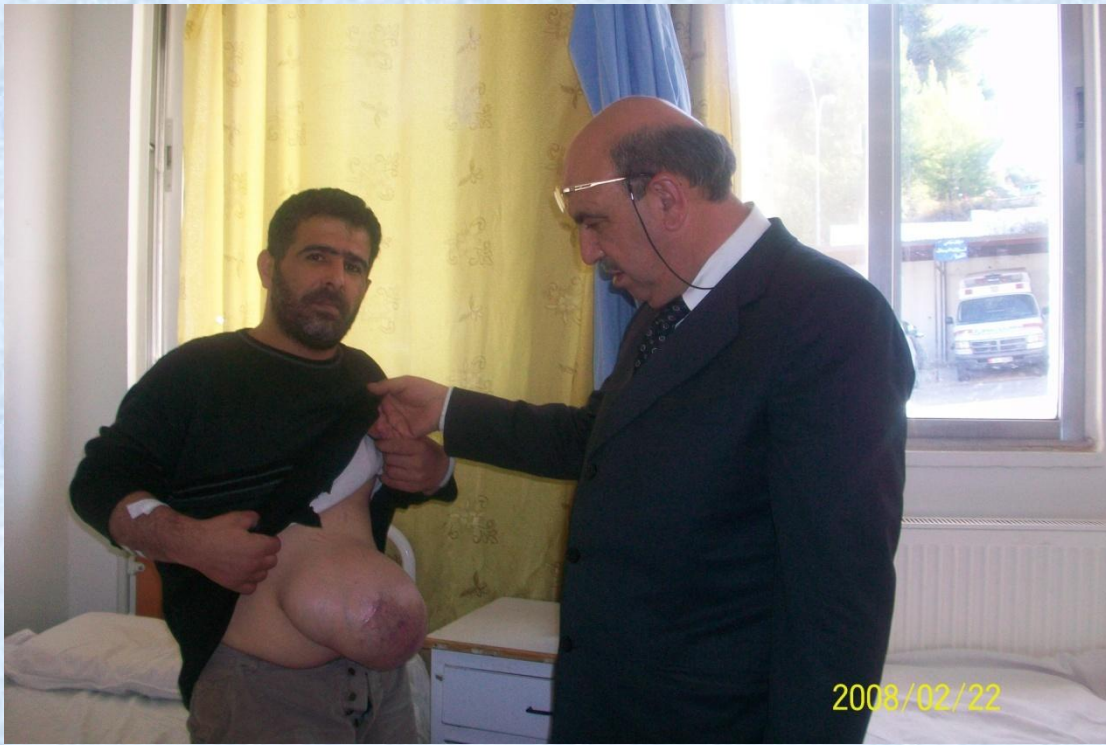أعداد عمليات الدكتور احمد الزغول موزعه
حسب الأعوام 2010 – 2000



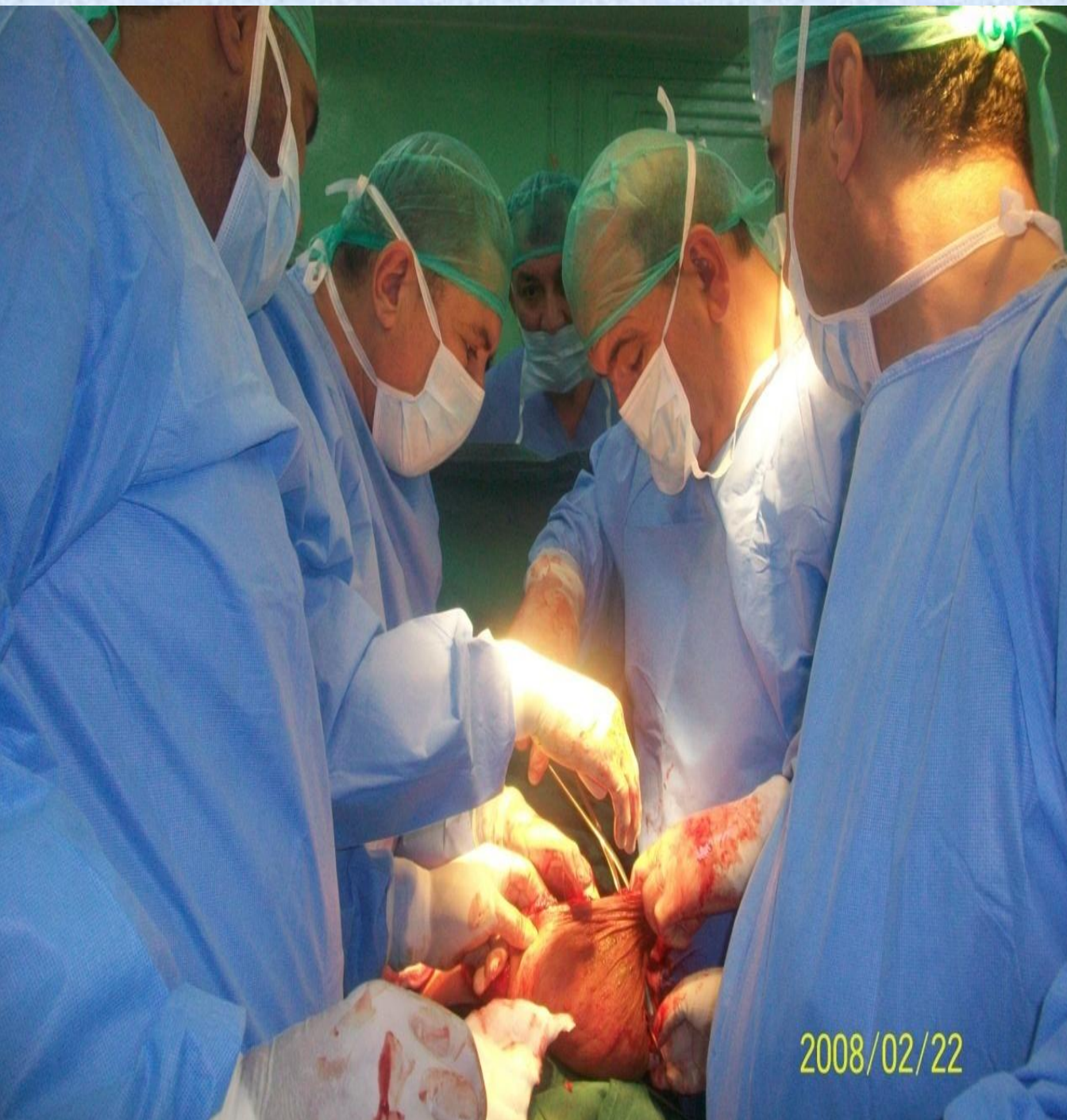أعداد عمليات الدكتور احمد الزغول موزعه

حسب الجنس ذكر , أنثى

الفصل الثاني
بعض العمليات الجراحية أأخرجه
(CRITICAL CACES)



صورة مريض يعاني من فتق في الصره (umbilical hernia)



(1)

اسم المريض : ع - ش - م - بع

العمر : 34 سنة

الجنس : انثى

الجنسية : اردنيه

رقم الملف : 53623

الحاله الاجتماعيه : عزباء

تاريخ الدخول : 2006\10\16

تاريخ الخروج : 2006\10\31

العنوان : الهاشميه

Past medical hx ---- FREE no any past medical illness

Present medical hx---- pt arrived to E.R as a case of RTA
pt was shocked, semiconscious,

Un recordable BP , tachy cardia pulse
140\m , sever pale , sweating & no
urine out put , no motor sensation ,
good breathing & good air entry .X
Rays show Open pelvic fracture .

Pt sent to theater operation room as atop emergency case .

Findings ----

- pt was resuscitated by three I.V lines I.V fluids & blood transfusion and haes. Laparatomy was done .
- about 4 liters of blood in the abdomen
- lacerated wound of major blood vessels at the bifurcation of the AORTA & communication of major lower blood vessels .

Management ---

- Resuscitation of the pt by I.V fluids & Massive blood transfusion about 20 units of whole blood & plasma & packed Red blood Cells was given .
 - Repair of lacerated blood vessels .
 - two big Drain tubes put on the abdomen .
 - post surgery pt sent to ICU department for critical follow up.
- *** second day after surgery : pt was conscious oriented V\S was stable good urine out put , then pt was followed up for 2 weeks and discharged & transferred to AL ESRAE hospital for open pelvic fracture management on discharge pt was stable & well .

*** after 3 months pt was followed up on the clinic & she was transferred for vascular surgeon to evaluate her vascular injury .

(2)

اسم المريض : ي - أ - ع - ز

العمر : 19 سنه

الجنس : ذكر

الجنسيه : اردني

رقم الملف : 53751

الحاله الأتماعيه : أعزب

تاريخ الدخول : 2008\4\30

تاريخ الخروج : 2008\5\14

العنوان : عنجره

Past medical hx ---- FREE no any past medical illness

Present medical hx---- pt arrived to E.R as a case of gun shot in the Rt upper Abdomen

pt was shocked, semiconscious,

BP 80\30 , tachy cardi 120\m , sever

pale , sweating & Pt sent to theater

operation room as a case of top

emergency.

Findings ---- - Rt lob of the liver tear 3 cm

- penetration of the G.B
- penetration of the inferior parts of the head of pancreas.
- 2 puncture 2 cm in the medial part of the duodenum & lateral to the ureter & anterior to the lower part of Rt kidney
- active bleeding & wounds 3 liters of blood in the abdomen .

Management ----

- * Repair of the liver tear was don.
- * Cholecystectomy was don .
- * Repair of the pancreas was don .
- * Repair of the 2 puncture of the duodenum was don .
- * Gastrogeogenostomy was don .
- * Exploration to the Rt kidney was don .
- * Washing the Abdomen & 3 drains was put on.
- * Pt was received 2 unit of blood & haes & I.V fluids
- post surgery pt sent to ICU department for critical follow up.

*** second day after surgery : pt was conscious oriented
V\S was stable good urine out put , then pt was
followed up for 2 weeks and discharged .

*** followed up on the clinic & he was no any
complications .

(3)

اسم المريض : ف - أ - م - ن

العمر : 53 سنة

الجنس : انثى

الجنسية : اردنيه

رقم الملف : 9582005899

الحاله الأتماعيه : متزوجه

تاريخ الدخول : 2010\10\11

تاريخ الخروج : 2010\10\27

العنوان : حلاوه

Past medical hx ---- FREE no any past medical illness

Present medical hx---- pt came for follow up in the surgical clinic was complaining of recurrent epigastric pain & vomiting & anorexia .

Clinically V\S was normal all lab results was normal except mild anemia HB 9% & on exam was mild distended abdomen .

U\S show evidence of acute cholecystitis & gall bladder stones .

Management ---

Transferred to Princes Basmas Hospital for farther investigations to roll out colonic tumors . After 10 days she return back on same picture complaining of abdominal pain , vomiting , & anorexia . And without any investigations don at Princes Basmas Hospital .

Plain Abdomen X Ray was don & show dilated small bowel lobes .

Decision was to do laparotomy to roll out colonic tumors . The operation was on 19\10\2010 .

Findings ---- - acute cholecystitis with gall bladder stons

- Rt hepatic flecture , colonic tumors
- mesenteric lymph node enlargement .
- Rt hemicolyctomy was done end to end anastomosis .

Pathology results was adeno carcinoma as it was expected . and then pt was transfiered to Al Basheer Hospital for farther managements .

(4)

اسم المريض : ث - ر - أ - س

العمر : 15 سنة

الجنس : ذكر

الجنسية : اردني

رقم الملف : 65609

الحاله الأتماعيه : أعزب

تاريخ الدخول : 2009\10\7

تاريخ الخروج : 2009\10\20

العنوان : اوصره

Past medical hx ---- FREE no any past medical illness

Present medical hx---- pt was presented to the
Emergency department with
multiple deep stab wounds
shocked Pt hypotension BP 60\20
mmHg , pulse 110\m , dyspnea ,
sweating , & pale .

The wounds were :

- multiple left posterior chest penetrating wounds with massive pneumothorax & hemothorax .
- neck stab wound , left submandibular active bleeding wound .
- back stab wound .
- abdominal stab wound .

So pt sent to operation room as atop emergency case

Findings -----

- Exploration to the wounds of the neck
- Lacerated internal jugular & branches of external jugular .
- Chest cavity was full of blood oozing of inter costal vessels at the site of stab wounds .
- abdominal wound was superficial .

Management ---

- * resuscitated the Pt by I.V fluids , I.V blood transfusion & plasma about 27 units was given to the Pt .
- * Repair of the lacerated major vessels & ligation of the branches of the external jugular performed .
- * ligation of the oozing vessels of inter costal vessels at the site of stab wound .

* drain the chest cavity by bilateral chest tubes . the chest tubes drain minimal amount of blood at the time of exploration of the neck wounds , after 3 hours the drain became filled about one liter of blood so thoractomy was don .

*** follow up in the clinic was don no any complications occur , stable condition , no any complains .

(5)

اسم المريض : ع - خ - ع - م

العمر : 5 سنوات

الجنس : ذكر

الجنسية : اردني

رقم الملف : 2001087800

الحاله الاجتماعيه : أعزب

تاريخ الدخول : 2010\10\30

تاريخ الخروج : 2010\11\1

العنوان : صخره

Past medical hx ---- history of congenital glycoma ,
history of operation both eyes ,
history of herniatomy one year ago .

Present medical hx ---- recurrent right inguinal hernia
& abdominal pain .

So arranged to do herniatomy

Findings ---- --

huge sliding recurrent hernia with
adhesion adherent to the appendix

Management --- so appendectomy was don & Repair of
the hernia was don .

*** Pt was followed up in the clinic no any complains &
no any complications .

(6)

اسم المريض : ب - ف - ض - م

العمر : 13 سنه

الجنس : انثى

الجنسيه : اردنيه

رقم الملف : 9992028872

الحاله الاجتماعيه : أعزب

تاريخ الدخول : 2010\9\30

تاريخ الخروج : 2010\10\8

العنوان : صخره

Past medical hx ---- history of appendectomy before 5 months

Present medical hx ---- Pt was complaining of abdominal pain , vomiting , and mild distended abdomen .

pt was admitted to female surgical ward & treated conservatively by I.V fluids & naso gastric tub , but

after 3 days Pt continuous had abdominal colic with active bowel sounds & looked cytosis .

So the decision was to do laparotomy

Findings ---- --

Closed terminal Ilium lobe gangrene by fibrous band about 3 cm of ileocecal valve .

Management ---

Resection of gangrenous lob end to end anastomosis .

*** Pt was followed up in the clinic no any complains & no any complications .

(7)

اسم المريض : ه - غ - م - ع

العمر : 68 سنة

الجنس : انثى

الجنسية : اردنيه

رقم الملف : 9432002112

الحاله الاجتماعيه : متزوجه

تاريخ الدخول : 2010\11\26

تاريخ الخروج : 2010\12\6

العنوان : الوهادنه

Past medical hx ---- history of diabetic mellitus type 2 10 years ago .

Present medical hx ---- Pt was complaining of abdominal pain , vomiting , and distention without local tenderness .

Plain abdomen X Ray show dilated lobes & picture of intestinal obstruction . So laparatomy was decided & don on 28\11\2010

Findings -----

Ilio cecal stocked mass with dilated small bowels & metastasis nodules in peritoneal cavity & the liver .

Management ---

Palliative surgery was don side to side anastomosis by bas the obstructed mass & then Pt discharged well .

*** Pt was followed up in the clinic no any complains & no any complications .

(8)

اسم المريض : أ - ح - م - ج

العمر : 27 سنه

الجنس : ذكر

الجنسيه : اردني

رقم الملف : 47752

الحاله الأتماعيه : أعزب

تاريخ الدخول : 2007\3\2

تاريخ الخروج : 2007\3\6

العنوان : كفرنجه

Past medical hx ---- free no history of past medical illness , no history of past surgery.

Present medical hx ---- Pt arrived to Emergency department at 11 PM as a case of lift deep stab wound in the neck Pt was semiconscious ,

shocked Pt , tachy cardia pulse
110 \ M , hypotension Bp
60\40 mmHg . so decided to
sent to operation room as a
top emergency case .

Findings ----

bleeding from the carotid branches

Second day of surgery Pt was full conscious
and oriented V\S were stable but Pt had lower
and upper limb weakness & weakness of the
muscle of the anal sphincter . So decided to
refer Pt to King ABDULAH Hospital for farther
investigation & evaluation from neuro surgeon
to roll out spinal cord injury .

Management ---

Ligation to the carotid bleeding branches was done &
then refer Pt to King ABDULAH Hospital for farther
investigation & evaluation from neuro surgeon
to roll out spinal cord injury .

*** Pt was followed up in the clinic no any complains &
no any complications his neurological injury improved
gradually .

(9)

اسم المريض : م - ع - م - ح

العمر : 40 سنة

الجنس : ذكر

الجنسية : اردني

رقم الملف : 9711023985

الحاله الأتماعيه : متزوج

تاريخ الدخول : 2010\11\26

تاريخ الخروج : 2010\12\2

العنوان : صخره

Past medical hx ---- free no history of past medical illness , no history of past surgery.

Present medical hx ---- Pt was complain of huge abdominal swelling 20 * 20 cm diagnosed as irreducible

umbilical hernia for surgery on
27\11\2010 .

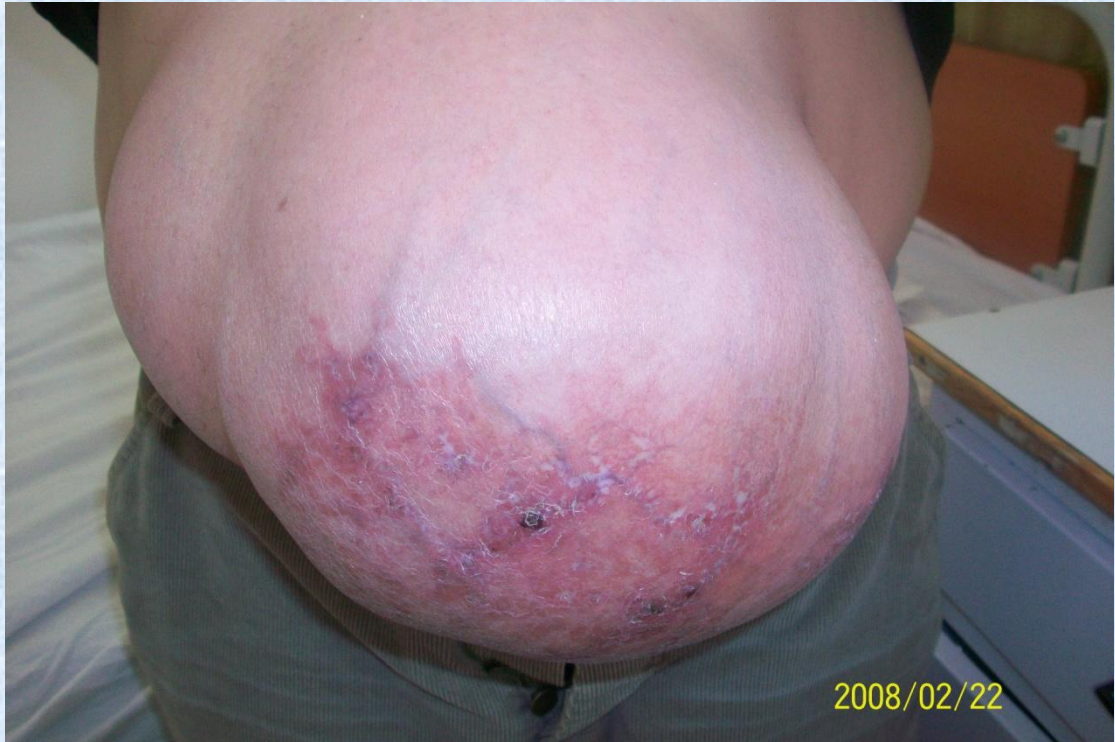Findings -----

Huge irreducible adherent hernia with transverse colon and small bowel where in the sac and reactionary ascetic fluids in the abdomen .

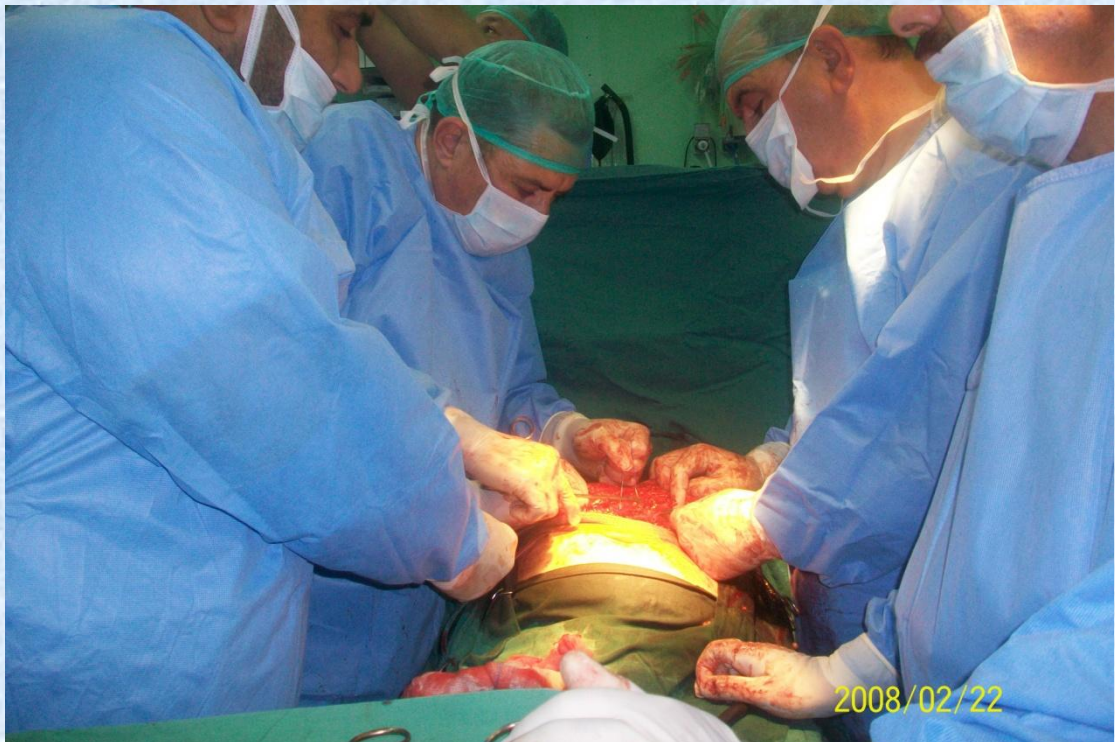Management ---

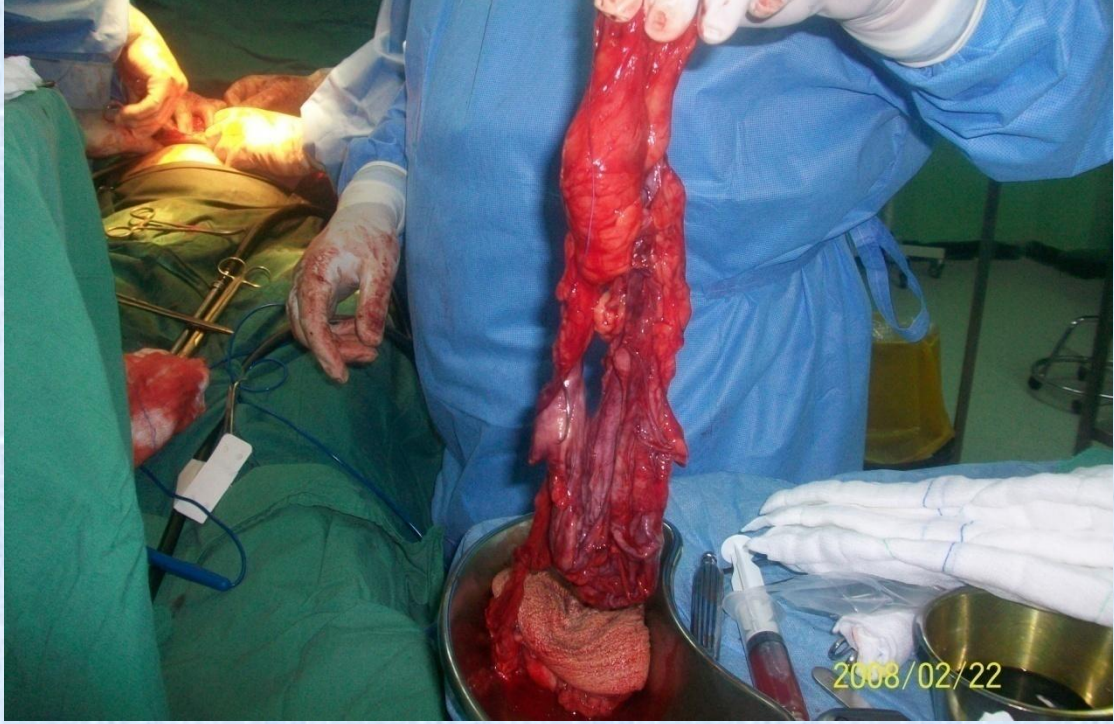- release the adhesion .
- Appendectomy was done .
- Reduction to the colon & small bowel

*** Pt was followed up in the clinic no any complains & no any complications .



صورة المريض قبل العمليه





صورة نفس المريض اثناء العمل الجراحي

(10)

اسم المريض : ز - ي - م - ط

العمر : 5 سنوات

الجنس : ذكر

الجنسيه : اردني

رقم الملف : 46411

الحاله الأتماعيه : أعزب

تاريخ الدخول : 2006\12\22

تاريخ الخروج : 2006\12\29

العنوان : صخره

Past medical hx ---- free no history of past medical illness , no history of past surgery.

Present medical hx ----

Pt arrived to Emergency department at 10 Am as a case of RTA complaining of lower abdominal pain with supra pubic region sever tenderness , conscious and oriented well V\S were stable HB was 13,6 . evaluated by the surgeon decided was to admitted him for observations .

Second day 10 AM Pt was evaluated by DR AHMED Pt was tachy cardia , pulse 130 \ M , conscious & oriented & complain of tenderness all over the abdomen HB dropped from 13,6 % to 9,1 % .

U\S show collection of fluids in the abdomen . So the decision was to sent Pt to theater for laparatomy

Findings ---- --

Second degree splenic injury

Management ---

-laparatomy was done & splenectomy was done

*** Pt was followed up in the clinic no any complains &
no any complications .

(11)

اسم المريض : س - ا - م - ع

العمر : 40 سنه

الجنس : انثى

الجنسيه : اردنيه

رقم الملف : 23398

الحاله الأجماعيه : متزوجه

تاريخ الدخول : 2007\7\21

تاريخ الخروج : 2007\7\26

العنوان : صخره

Past medical hx ---- past history of umbilical hernia repair & history of caesarian section five years ago .

Present medical hx ---- Pt complained of epigastric swelling on standing , diagnosed as huge epigastric Hernia , & decided was for surgery on 22\7\2007 .

Findings ---- --

Multiple supra umbilical defect with huge sac with adherent omentum .

Management ---

Mish Repair was done under epidural anesthesia .

*** Pt was followed up in the clinic no any complains & no any complications .

(12)

اسم المريض : ب - ح - س - خ

العمر : 47 سنه

الجنس : انثى

الجنسيه : اردنيه

رقم الملف : 40860

الحاله الأجماعيه : متزوجه

تاريخ الدخول : 2006\11\26

تاريخ الخروج : 2006\12\13

العنوان : كفرنجه

Past medical hx ---- past history of cystocell repair 6 monthes ago & no menses since that time .

History of mild falling down 3 days ago

Present medical hx ----

Pt arrived to emergency department complain of mild abdominal pain ,mild distension , & supra pupic mild tenderness with fullness . and history of mild falling down 3 days ago , no changing in bowel habits P-R free , HB 7% , PCV 22% , in urine analysis WBCs numerous .V\S were stable .

decision was to admitted the Pt for observation , & conservative treatment was started .

on 30\11\2006 Pt developed sever loin pain hypotension BP 80\50 , Pulse 100\m , U\S showed pelvic collection . So laparatomy was decided .

Findings ---- --

- Late splenic rupture hematoma .
- 2 liter of blood collection in the abdomen .
- rupture spleen .

Management ---

Splenectomy was done , & 8 units of blood was given .

*** Pt was followed up in the clinic no any complains & no any complications .

(13)

اسم المريض : س - م - م - ز

العمر : 29 سنه

الجنس : انثى

الجنسيه : اردنيه

رقم الملف : 51925

الحاله الأجماعيه : مطلقه

تاريخ الدخول : 2007\9\22

تاريخ الخروج : 2007\9\29

العنوان : عنجره

Past medical hx ---- past history of Appendectomy 5 years ago .

History of gluteal injection 1,5 years ago lead to swelling at the site of injection this swelling gradually increased in size .

Present medical hx ----

pt was admitted to female surgical ward complain of Rt gluteal mass 10*10*8 cm deep to soft tissue the gluteal mass was soft & not tender . so decision was to admitted the Pt for surgery to roll out malignancy .

Findings ---- --

Huge mixture tissues in the deep gluteal muscle 10*10*8 cm .

Management ---

Excision to this mass and surrounding tissues was done and sent for pathological studies .

The result was that Pt had sarcoma so Pt was referral to AL BASHEER Hospital for farther management needs

*** Pt was followed up in the clinic no any complains & no any complications & Radio therapy was given .

(14)

اسم المريض : ح - س - ا - ز

العمر : 61 سنه

الجنس : انثى

الجنسيه : اردنيه

رقم الملف : 9462005343

الحاله الأجماعيه : متزوجه

تاريخ الدخول : 2007\6\19

تاريخ الخروج : 2007\7\3

العنوان : عنجره

Past medical hx ---- free no history of past medical illness , no history of past surgery.

Present medical hx ---- Pt was admitted to female medical ward complained of abdominal pain , V\S were normal & all lab results were normal .

20\6\2007 surgical consultation was done , U\S result was free (normal)

Plain Abdomen X Ray was done and there is a signs of intestinal obstruction .

So the decision was to do laparatomy on 21\6\2007 to roll out colonic tumors .

Findings ---- --

Sigmoid tumor completely obstructed of the lumen with no metastasis , no mesenteric lymph node enlargement

Management ---

- Sigmoidectomy end to end anastomosis was done

- Cholecystectomy was done .

The result was that Pt had malignant tumor so Pt was referral to AL BASHEER Hospital for farther management needs

*** Pt was followed up in the clinic no any complains & no any complications .

(15)

اسم المريض : خ - ح - ت - ل

العمر : 26 سنه

الجنس : ذكر

الجنسيه : اردني

رقم الملف : 51870

الحاله الأجماعيه : أعزب

تاريخ الدخول : 2007\9\19

تاريخ الخروج : 2007\9\25

العنوان : اربد

Past medical hx ---- past history of herniatomy in the childhood .

Present medical hx ---- Pt arrived to emergency department post epigastric stab wound . Pt was complaining of tachy pnea , active bleeding from the wound site , epigastric tenderness .

BP was 150\90 mmHg , pulse 120\m , R.R 28\m no signs of hemo thorax , & no signs or symptoms of neumthorax .

Decided was to sent to theater state .

Findings ---- --

Just penetrating without organ injury

Management ---

Stopped bleeding , suturing the wound , & dressing .

*** Pt was followed up in the clinic no any complains & no any complications .

(16)

اسم المريض : ف - ش - م - ص

العمر : 26 سنه

الجنس : ذكر

الجنسيه : اردني

رقم الملف : 40113

الحاله الإجتماعيه : أعزب

تاريخ الدخول : 2006\1\28

تاريخ الخروج : 2006\2\5

العنوان : عجلون

Past medical hx ---- free no past history of medical illness no past history of surgery .

Present medical hx ---- Pt arrived to emergency department as a case of quarrel complain of multiple stab wounds some of it penetrating to the abdomen. Pt was pale , BP 110\60 mmHg & started to drop until 90\45 mmHg , Pulse 90 \ m,

conscious & oriented , HB was 14,8% then dropped to 8,2 % .

Decision was to sent to theater as a top emergency case.

Findings ----

- lift to posterior lower chest lift to thoracic spine 7 cm inter coastal space but not penetrating to the chest cavity but deep up wound to the lift spine

- right 8th coastal posterior space penetrating to the chest cavity but good air entering bilateral .
- lift apex of the axilla deep reaching to posterior axillary line and up .
- small superficial wound lift lateral lift eye .
- lift index small cut wound .
- liver posterior surface tear .

Management ---

- * repair of the liver tear .
- * suturing & dressing other wounds
- * bleeding stopped & Pt was given 5 units of I.V blood transfusion .

تم تحويل المريض الى ما الأمير راشد العسكري لأنه ما زال على رأس عمله .

(17)

اسم المريض : م - ن - خ - ص

العمر : 25 سنة

الجنس : ذكر

الجنسية : اردني

رقم الملف : 43574

الحاله الأجماعيه : أعزب

تاريخ الدخول : 2006\7\23

تاريخ الخروج : 2006\7\30

العنوان : عجلون

Past medical hx ---- free no past history of medical illness & no past history of surgery . history of heavy smoker .

Present medical hx ---- Pt arrived to emergency department complained of sudden onset of sever epigastric pain radiated to the back with vomiting . V\S were normal &

standing C X Ray show air under diaphragm .

Decision was to prepare for surgery state .

Findings ---- -- Perforated duodenal ulcer .

Management --- repairing was done .

*** Pt was followed up in the clinic no any complains & no any complications .

(18)

اسم المريض : ث - ر - م - ز

العمر : 13 سنه

الجنس : ذكر

الجنسيه : اردني

رقم الملف : 43271

الحاله الأجماعيه : أعزب

تاريخ الدخول : 2006\7\7

تاريخ الخروج : 2006\7\11

العنوان : عنجره

Past medical hx ---- free no past history of medical illness & no past history of surgery . history of heavy smoker .

Present medical hx ---- Pt arrived to emergency department as a case of quarrel complained of lift upper quadrant 3 cm stab wound & bleeding from this wound . BP was 100\60 mmHg & pulse 100 \ m , pale , conscious & oriented .

Decision was to sent to theater state .

Findings ---- --

just penetrating intra abdominal stab wound without intra abdominal organs injury .

Management ---

Exploration suturing & wound dressing .

*** Pt was followed up in the clinic no any complains &
no any complications .

(19)

اسم المريض : ح - س - أ - ب

العمر : 17 سنه

الجنس : ذكر

الجنسيه : اردني

رقم الملف : 35899

الحاله الاجتماعيه : أعزب

تاريخ الدخول : 2005\7\11

تاريخ الخروج : 2005\8\2

العنوان : كفرنجه

Past medical hx ---- free no past history of medical illness & no past history of surgery .

Present medical hx ---- Pt arrived to emergency department as a case of shot gun in upper abdomen in epigastric lift to out let , posterior back , colon out side the wound . Pt was sweating pale shocked ,Bp 50\20 mmHg hypotension, pulse 120 \m

Pt was resuscitated immediately by 3 lines I.V fluids & I.V blood transfusion & sent to theater as a top emergency case .

Findings ---- --

- about 4 liters of blood in side the abdomen
- lacerated greater curvature of the stomach

- lacerated transverse & splenic frictur
- multiple first jejunum wound .
- fourth part of the duodenum injury .
- lift kidney injury .
- splenic laceration .

Management ---

- debridement of the lacerated wound of the stomach& repair .
- transverse colectomy & right side colostomy .
- right side colostomy + distal sigmoid as heart man pouch .
- closed to perforated duodenum
- resection of 50 cm of jejunum end to end anastomosis
- simple closure to perforated jejunum
- exploration to the lift kidney injured & repair
- Posterior loin wound repaired & drained .

*** Pt was followed up in the clinic no any complains no any complications . & Pt was readmitted on 21\1\2006 for closure to colostomy was done & Pt was discharged on 10\2\2006 without any complications .

(20)

اسم المريض : م - م - أ - ش

العمر : 42 سنة

الجنس : انثى

الجنسيه : اردنيه

رقم الملف : 15866

الحاله الاجتماعيه : متزوجه

تاريخ الدخول : 2006\2\8

تاريخ الخروج : 2006\2\23

العنوان : كفرنجه

Past medical hx ---- free no past history of medical illness & no past history of surgery .

Present medical hx ---- Pt was admitted for female surgical ward complained of thyroid enlargement & for operation thyroidectomy .

Findings ---- -- cystic huge cystic with lobe thyroid cyst

Management --- total lift lobectomy .

*** Pt was followed up in the clinic no any complains & no any complications .

(21)

اسم المريض : أ - ع - م - ن

العمر : 36 سنه

الجنس : ذكر

الجنسيه : اردني

رقم الملف : 43961

الحاله الأتماعيه : متزوج

تاريخ الدخول : 2006\8\16

تاريخ الخروج : 2006\8\23

العنوان : عجلون

Past medical hx ---- past history of uriteric stones with operation on right kidney .

Present medical hx ---- Pt arrived to emergency department complained of sever abdominal pain and vomiting . plain abdomen X Ray show air flow level .

Decision was to do operation tomorrow .

Findings ---- --

- adhesive intestinal obstruction , adhesive small bowel obstruction .

Management ---

Release of adhesive bands

*** Pt was followed up in the clinic no any complains & no any complications .

(22)

اسم المريض : ع - م - س - م

العمر : 17 سنه

الجنس : ذكر

الجنسيه : اردني

رقم الملف : 31202

الحاله الأجماعيه : أعزب

تاريخ الدخول : 2004\12\4

تاريخ الخروج : 2004\12\11

العنوان : عين جنا

Past medical hx ---- no past history of medical illness
no past history of previous surgery .

Present medical hx ---- Pt arrived to emergency
department complained of
epigastric pain since 3 days
ago then shifted to right side
abdominal pain mainly in the
right iliac fossa pain . V\S were
stable , a febrile C X Ray standing
no air under diaphragm lab result
urine analysis free & leucocytosis .

Decision was to admitted the patient to roll out acute
appendicitis . Pt was admitted to operation room at
10.30 Pm until 2 Am

Findings ---- --

Perforated duodenal ulcer .

Management ---

- appendectomy was done
- simple closure of duodenal ulcer with omentum patch

- drain was put on left sub hepatic area .

*** Pt was followed up in the clinic no any complains &
no any complications .

(23)

اسم المريض : ح-م-أ-ق

العمر : 20 سنه

الجنس : ذكر

الجنسيه : اردني

رقم الملف : 24503

الحاله الإجتماعيه : أعزب

تاريخ الدخول : 2004\2\1

تاريخ الخروج : 2004\2\5

العنوان : عين جنا

Past medical hx ---- no past history of medical illness
no past history of previous surgery .

Present medical hx ---- Pt arrived to emergency
department after penetrating
abdominal stab wound on left to
umbilical with omentum out
side of the wound , patient was
conscious & oriented , V\S
were stable .

Decision was to sent to theater state .

Findings ---- --

Just wound penetrating with out internal organs injury .

Management ---

Just laparatomy exploration & drainage .

*** Pt was followed up in the clinic no any complains &
no any complications .

(24)

اسم المريض : أ - م - أ - غ

العمر : 2 سنه

الجنس : ذكر

الجنسيه : اردني

رقم الملف : 24783

الحاله الأتماعيه : أعزب

تاريخ الدخول : 2004\2\14

تاريخ الخروج : 2004\2\27

العنوان : الهاشميه

Past medical hx ---- no past history of medical illness
no past history of previous surgery .

Present medical hx ---- Pt arrived to emergency
department complained of
abdominal pain & abdominal
distension and coffee ground
vomiting , Pt was admitted to
pediatric ward for investigations
then surgical consultation was
done . Pt was dyspneic due to

abdominal distension & looks dehydrated , plain
abdomen X Ray showed dilated loop.

Decision was to transfer the Pt to surgical ward to be
followed up by the surgeon to roll out Mickles
Diverteculum .The operation was at 3 Am .

Findings ---- --

- gangrenous Mickles Diverteculum with obstruction
band completely .
- serous fluids in the abdomen .

- dilated small bowel loop .
- Gangrenous Mickels with band completely obstructed the lumen 30 cm from the terminal iliac .

Management ---

- appendectomy was done .
 - excision of the band.
 - Mickles Diverteculum widge resection end to end anastomosis .
 - drainage the abdomen .
- *** Pt was followed up in the clinic no any complains & no any complications .

(25)

اسم المريض : م - أ - س - ق

العمر : 90 سنه

الجنس : ذكر

الجنسيه : اردني

رقم الملف : 25705

الحاله الاجتماعيه : متزوج

تاريخ الدخول : 2004\3\26

تاريخ الخروج : 2004\4\6

العنوان : عين جنا

Past medical hx ---- past history of hypertension ,
history of urinary bladder cancer
was treated by radiotherapy .

Present medical hx ---- Pt arrived to emergency
department complained of
sever abdominal pain & nausea .
clinically tender all over the
abdomen , slight bowel sound,
Bp 190\100 mmHg , C X Ray
standing show bilateral air
under diaphragm , lab results

within normal ,Amylase normal U\S result lift kidney
stones multiple variable size .

Decision was to prepare for surgery .

Findings ---- --

- serous ascetic fluids in the abdomen
- adhere with swollen pancreas .
- congested appendix .
- and normal stomach .

Management ---

- appendectomy was done .
 - release of adhesive band .
 - drainage of fluids by drain in the pelvis & drain in the right sub hepatic .
- *** Pt was followed up in the clinic no any complains & no any complications .

(26)

اسم المريض : خ - ط - م - س

العمر : 70 سنه

الجنس : ذكر

الجنسيه : اردني

رقم الملف : 28242

الحاله الاجتماعيه : متزوج

تاريخ الدخول : 2004\7\17

تاريخ الخروج : 2004\7\21

العنوان : ارحابا

Past medical hx ---- past history of hypertension .

Present medical hx ---- Pt was admitted to surgical department as a case of left inguinal hernia for surgery tomorrow . C X Ray showed cardio megally & pt had ECG changes .

Decision was to prepare the Pt for surgery tomorrow .

Findings ---- --

- Direct + sliding hernia .
- cord lipoma

Management ---

- excision for the lipoma .
- herniatomy .
- darling repair.

*** Pt was followed up in the clinic no any complains & no any complications .

(27)

اسم المريض : أ - م - م - س

العمر : 11 سنه

الجنس : ذكر

الجنسيه : اردني

رقم الملف : 27023

الحاله الاجتماعيه : أعزب

تاريخ الدخول : 2004\5\22

تاريخ الخروج : 2004\5\29

العنوان : عنجره

Past medical hx ---- free no past history of medical illness & no past history of surgery .

Present medical hx ---- Pt arrived to emergency department complained of abdominal pain & vomiting . clinically Pt was dehydrated tender abdomen & rebound positive .

Decision was to admitted the Pt to roll out complicated appendicitis .

Findings ---- --

- perforated appendix with generalized peritonitis .
- mickels diverticulum not inflamed .

Management ---

-appendectomy was done .

Lavage the abdomen & 2 drains was put on .

-wedge resection of mickels diverticulum with anastomosis

*** Pt was followed up in the clinic no any complains &no any complications .

(28)

اسم المريض : ح - ع - أ - ز

العمر : 76 سنه

الجنس : ذكر

الجنسيه : اردني

رقم الملف : 27325

الحاله الاجتماعيه : متزوج

تاريخ الدخول : 2004\6\5

تاريخ الخروج : 2004\6\8

العنوان : عنجره

Past medical hx ---- past history of bilateral inguinal
hernia repaired when he was 50

years old , & chronic heavy smoker .

Present medical hx --- Pt was admitted to male surgical department as a case of acute irreducible left inguinal hernia which produced since 3 hours before admission & followed by vomiting , abdomen mild

distended , soft lax & tender huge irreducible hernia .

Decision was to send to theater state for surgery under spinal anesthesia .

Findings -----

- obstructed recurrent sliding hernia .

Management ---

*reduction + repair

*** Pt was followed up in the clinic no any complains & no any complications .

(29)

اسم المريض : س - ج - س - ز

العمر : 22 سنه

الجنس : انثى

الجنسيه : اردنيه

رقم الملف : 28853

الحاله الاجتماعيه : عزباء

تاريخ الدخول : 2004\8\13

تاريخ الخروج : 2004\8\19

العنوان : كفرنجه

Past medical hx ---- no past history of medical illness
no past history of previous surgery .

Present medical hx ---- Pt was admitted to female
surgical department
complained of sever lower
abdominal pain with mild
tenderness & mild rebound .
WBC 12400 , urine free, PCV dropped from 28% -- 24% .

Decision was to prepare Pt for surgery to roll out
complicated appendicitis .

Findings ---- --

- blood in the pelvis
- normal appendix
- Twisted hemorrhagic right ovarian cyst .
- normal terminal ileum .

Management ---

- appendectomy was done .
- right ovariactomy with cystectomy was done .
- evacuation of the blood .
- and blood transfusion 2 units were given .

*** Pt was followed up in the clinic no any complains & no any complications .

(30)

اسم المريض : س - ع - م - م

العمر : 86 سنة

الجنس : انثى

الجنسية : اردنيه

رقم الملف : 29039

الحاله الاجتماعيه : متزوجه

تاريخ الدخول : 2004\8\21

تاريخ الخروج : 2004\8\26

العنوان : عنجره

Past medical hx ---- no past history of medical illness
no past history of previous surgery .

Present medical hx ---- Pt was admitted to female
surgical department
complained of mass in the
left breast for excision .

Decision was to prepare Pt for surgery .

Findings ---- --

Rebound mass behind the nipple .

Management ---

-excision to the mass with midle upper quadrectomy &
lumpectomy .

*** Pt was followed up in the clinic no any complains &
no any complications .

(31)

اسم المريض : ف - ا - م - ز

العمر : 77 سنه

الجنس : انثى

الجنسيه : اردنيه

رقم الملف : 29040

الحاله الاجتماعيه : متزوجه

تاريخ الدخول : 2004\8\21

تاريخ الخروج : 2004\8\27

العنوان : عنجره

Past medical hx ---- no past history of medical illness
no past history of previous surgery .

Present medical hx ---- Pt was admitted to female
surgical department
complained of recurrent right
upper quadrant pain &
tenderness U\S show multiple
gall bladder stones .

Decision was for cholecystectomy tomorrow .

Findings ---- --

- severely distended adhere gall bladder to the around structures & common bile duct looks dilated .
- cholecystitis & empyema of the gall bladder

Management ----

- reduce the adhering .
 - complete dissection of the gall bladder .
- *** Pt was followed up in the clinic no any complains &
no any complications .

(32)

اسم المريض : ا - ر - م - ر

العمر : 18 سنه

الجنس : انثى

الجنسيه : اردنيه

رقم الملف : 23814

الحاله الاجتماعيه : متزوجه

تاريخ الدخول : 2003\12\29

تاريخ الخروج : 2004\1\3

العنوان : كفرنجه

Past medical hx ---- no past history of medical illness
no past history of previous surgery .

Present medical hx ---- Pt arrived to emergency
department Pregnant full term
complained of sever right side
abdominal pain . Pt was
evaluated by the gynecologist &
the surgeon .

Decision was to sent to theater state for cesarean
section & to roll out complicated appendicitis .

Findings ---- --

- right side peritonitis with obstructed congested appendix .
- full term baby alive

Management ---

- appendectomy was done
 - cesarean section was done baby alive
- *** Pt was followed up in the clinic no any complains &
no any complications .

(33)

اسم المريض : ل - ح - م - ص

العمر : 36 سنه

الجنس : انثى

الجنسيه : اردنيه

رقم الملف : 25527

الحاله الاجتماعيه : متزوجه

تاريخ الدخول : 2004\3\19

تاريخ الخروج : 2004\3\24

العنوان : عجلون

Past medical hx ---- no past history of medical illness
no past history of previous surgery .

Present medical hx ---- Pt arrived to emergency
department complained of

sever persistent right upper quadrant pain radiated to the back & associated with vomiting many times , temperature was 38 c , WBC 19200 , U\S showed

Distended gall bladder with multiple gall bladder stones clinically pt look in pain & feverish , palpable & tender gall bladder .

Decision was to admitted the Pt & to prepare for surgery

Findings ---- --

- hydrops of the gall bladder, normal liver , normal common bile duct .

Management ---

Cholecystectomy was done .

*** Pt was followed up in the clinic no any complains & no any complications .

(34)

اسم المريض : ف - س - م - و

العمر : 52 سنة

الجنس : انثى

الجنسية : اردنيه

رقم الملف : 24335

الحاله الاجتماعيه : متزوجه

تاريخ الدخول : 2004\1\24

تاريخ الخروج : 2004\1\31

العنوان : عجلون

Past medical hx ---- no past history of medical illness
no past history of previous surgery .

Present medical hx ---- Pt was admitted to female
surgical department complained
of multiple nodules goiter for
thyroidectomy tomorrow .

Decision was to prepare the Pt for surgery .

Findings -----

Multiple nodules goiter with huge prominent right lobe huge nodule .

Management ---

Near total thyroidectomy .

*** Pt was followed up in the clinic no any complains & no any complications .

(35)

اسم المريض : ش - ر - س - ق

العمر : 57 سنة

الجنس : انثى

الجنسية : اردنيه

رقم الملف : 31528

الحاله الاجتماعيه : متزوجه

تاريخ الدخول : 2004\12\18

تاريخ الخروج : 2004\12\27

العنوان : عين جنا

Past medical hx ---- chronic history of epigastric pain
which it was improved on famodar

Present medical hx ---- Pt arrived to emergency
department complained of
sudden onset of sever epigasrtic

pain associated with vomiting .
clinically gardill abdomen ,

tenderness all over the abdomen , standing C X Ray
showed air under diaphragm , lab results leukocytosis
WBC 14000 , tachy cardia & tachypnea .

Decision was to prepare Pt for surgery state .

Findings ---- --

Perforated duodenal ulcer the gastric contents sub
hepatic .

Management ---

Simple closure + omentum patch .

*** Pt was followed up in the clinic no any complains
&no any complications .

(36)

اسم المريض : خ - ح - ت - ل

العمر : 26 سنة

الجنس : ذكر

الجنسية : اردني

رقم الملف : 51870

الحالة الاجتماعية : أعزب

تاريخ الدخول : 2007\9\19

تاريخ الخروج : 2007\9\25

العنوان : اربد

Past medical hx ---- past history of

Present medical hx ---- Pt arrived to emergency
department

Decided was to sent to theater state .

Findings ---- --

Management ---

*** Pt was followed up in the clinic no any complains &
no any complications .

(37)

اسم المريض : خ - ح - ت - ل

العمر : 26 سنة

الجنس : ذكر

الجنسية : اردني

رقم الملف : 51870

الحاله الاجتماعيه : أعزب

تاريخ الدخول : 2007\9\19

تاريخ الخروج : 2007\9\25

العنوان : اربد

Past medical hx ---- past history of

Present medical hx ---- Pt arrived to emergency
department

Decided was to sent to theater state .

Findings ---- --

Management ---

*** Pt was followed up in the clinic no any complains &
no any complications .

(38)

اسم المريض : خ - ح - ت - ل

العمر : 26 سنه

الجنس : ذكر

الجنسيه : اردني

رقم الملف : 51870

الحاله الاجتماعيه : أعزب

تاريخ الدخول : 2007\9\19

تاريخ الخروج : 2007\9\25

العنوان : اربد

Past medical hx ---- past history of

**Present medical hx ---- Pt arrived to emergency
department**

Decided was to sent to theater state .

Findings -----

Management ----

*** Pt was followed up in the clinic no any complains &
no any complications .

(39)

اسم المريض : خ - ح - ت - ل

العمر : 26 سنه

الجنس : ذكر

الجنسيه : اردني

رقم الملف : 51870

الحاله الاجتماعيه : أعزب

تاريخ الدخول : 2007\9\19

تاريخ الخروج : 2007\9\25

العنوان : اربد

Past medical hx ----- past history of

Present medical hx ---- Pt arrived to emergency department

Decided was to sent to theater state .

Findings ---- --

Management ----

*** Pt was followed up in the clinic no any complains & no any complications .

(40)

اسم المريض : خ - ح - ت - ل

العمر : 26 سنه

الجنس : ذكر

الجنسيه : اردني

رقم الملف : 51870

الحاله الاجتماعيه : أعزب

تاريخ الدخول : 2007\9\19

تاريخ الخروج : 2007\9\25

العنوان : اربد

Past medical hx ---- past history of

Present medical hx ---- Pt arrived to emergency department

Decided was to sent to theater state .

Findings ---- --

Management ---

*** Pt was followed up in the clinic no any complains & no any complications .